

Histopathological study of delayed mustard gas keratopathy

Jadidi Kh.¹ MD, Sadeghipour A. R.² MD, Naderi M.* MD, Haghghi M.¹ MD, Rafizade P.¹ MD

*Department of Ophthalmology, Baqiyatallah Hospital, Baqiyatallah University of Medical Sciences, Tehran, Iran;

¹Department of Ophthalmology, Baqiyatallah Hospital, Baqiyatallah University of Medical Sciences, Tehran, Iran;

²Department of Pathology, Rasoul Akram Hospital, Iran University of Medical Sciences, Tehran, Iran

Abstract

Aims: Ocular injury by mustard gas (HD) leads to severe eye damage. Long term characterization of mustard gas ocular toxicity has not been described in detail yet. Present study was performed in order to explore chronic histological and immunopathologic effects of HD ocular exposure and try to find etiology for these effects.

Methods: This descriptive case study was performed on corneal and conjunctival samples of 22 chemical injured victims with late-onset keratopathy who needed surgical treatment between 1997 and 2007 in Baqiyatallah hospital. Samples were selected by simple sampling method. Both eyes underwent surgery in 7 cases; therefore 29 samples were delivered to pathology section. 29 limbus specimens were studied by light, direct immunofluorescence and electron microscopy.

Results: Histological findings revealed signs of chronic inflammation. Conjunctivalization, epithelial thinning and goblet cell depletion in light microscopy as well as corneal edema, basement membrane destruction and cytoplasmic vacuolization in electronic microscopy were dominant findings. Fluorescent microscopy demonstrated nonspecific changes.

Conclusion: There are no diagnostic histopathologic or microscopic findings in late-onset HD ocular injuries. According to our observations, neither humoral nor cell mediated immunity could explain all histological damages. It seems that primary alkalizing injury is the keystone of HD late-onset pathogenesis.

Keywords: Mustard Gas, Pathology, Eye

The lesions caused by chemical agents in military operations were first reported in the First World War I during 1914 to 1918 and with Chlorine gas. Since then, various chemical agents have been used in many wars. The most recent use of chemicals was during the Iraq war against Iran, which was applied at a large scale. According to the statistics of Iran-Iraq war, about one hundred thousand people have gone under treatment because of the acute complications of these drugs and since then, about thirty-four thousand of Iranians still suffer from the delayed complications [1]. Mustard Gas is one of the chemical agents that is placed among lethal gases and is considered as vesicant factors. This gas could be absorbed easily through inhale or contacting eyes, skin, or mucous membrane and damages the human's tissues with different mechanisms. The most sensitive body organs to Mustard Gas are eyes. The intensity of eye damages caused by the vapor mood of mustard depends on the concentration of the gas and duration of contact. Mustard Gas exposure causes acute pain, tears falling, photophobia, and blepharospasm in a few hours, and if the victim is opposed to high concentrations of this gas or liquid form of Sulfur Mustard, it would cause corneal edema, corneal ulcer, corneal perforation, and even blindness [2]. Stable corneal ulcer may occur 8 to 25 years after Mustard Gas exposure. This long-term keratopathy may also be accompanied with chronic

conjunctives, or corneal opacity. Although the effects of Mustard Gas are well known, studies on long-term effects of this gas are highly limited (after facing once or more) and cornea histopathology changes, conjunctiva in keratopathy or long-term kerato conjunctiva resulting from Mustard Gas specially at the level of florescence and electron microscopic have not been explained yet.

The eye's surface is normally covered with corneal epithelium and conjunctiva, both of which are of squamous. Non-keratinized, and the reconstruction process and surface repair of corneal epithelium is performed by stem cells in Limbus area (the connector epithelium of corneal and conjunctiva). The major pretences of Limbus defect or the so-called dysfunction of Limbus stem cells including recurrent corneal eversions, chronic inflammation in stroma accompanying with scar creation, and cornea scholarization, and before conjunctiva epithelium of the cornea (conjunctivalization) [3]. In acute forms of cornea diseases, losing all the stem cells of Limbus is observed. This lesion might appear due to different reasons such as chemical or thermal injuries, Steven Jonson syndrome, Cryotherapy, and long-term characterization of Mustard Gas. At the status quo, Allograft Limbus Transplantation (ALT) is a proved technique for treating one-way Limbus defect. This connection causes the cells with cornea epithelium

phenotype return as homogeneous accompanying with regress and scholarization, and cornea edema, while it does not cause any improvements in visual acuity [4]. Since keratopathy lesions resulting from mustard gas are mostly bi-lateral, in conducted studies in one of the military hospitals of Tehran, allograft Limbus transplantation was done, and the result of this study showed healing the injured epithelium of cornea, and clinical improving of the patients [5]. This study was aimed at studying the created histopathology changes in the patients' corneas suffering from long-term keratopathy caused by Mustard Gas that are the candidates for Allograft limbus Transplantation.

Methods

This is a descriptive case study that was done on cornea and conjunctiva cases of 22 chemical injuries suffering from Delayed Mustard Gas Keratopathy (DMGK), who needed surgical treatment during 1997-2007.

The subjects were selected by simple sampling. In seven cases both eyes were operated, therefore, a total number of twenty-nine samples were delivered to pathology ward.

Through Limbus area, cornea peripheral, and conjunctival involvement, biopsy was taken from Limbus corneal during the operation. The samples were sent to pathology ward to be analyzed in three levels using optical, florescence, and electron microscopes as follows;

1. The first sample was prepared in formalin solution 10% to be studied by optical microscopic. Paraffin block was prepared from this sample, and was stained through two methods of H & E and PAS. Other special colors such as trichrome was used as well during the performing this study. These samples were studied by optical microscopic (Olympus BH-2; Japan).

2. The second sample was frozen at -20 centigrade, and it was placed on slides stained by Poly-El-Lysine by cryostat. Then it was colored by florescence antibodies IgA, IgG, IgM, C1q, C3, C4, Ig total and fibrinogen. The samples were studied with florescence microscope (Germany; Zeiss Axioscop) and the results were recorded.

3. The third sample was processed after fixation in the place of Glutaraldehyde 2%. Then, section levels were prepared after making a resinal block with ultra micro tome by 60 nanometer thickness. After that, the samples were stained by uranyl-acetate and studied by electron microscope (Zeiss Em900; Germany).

Since it was the first time in Iran that cornea was studied by electron microscope, and the degenerative changes were logically expected in DMGK, sample

containers containing saline, formalin 10%, and glutaraldehyde were delivered to the operation room to minimize the changes caused by serotinous fixation. Then the surgeon placed the samples in proper containers and sent them to the pathology ward. Since the size of cornea samples are very small, the surgeon removed the minimum of corneal tissue and divided it, sometimes the sampling was done from different parts of Limbus and cornea. Therefore, in some cases the samples preparing for studying with optical microscopic, florescence, and electron were not from the same place and sometimes sent containers did not contain the considered tissue.

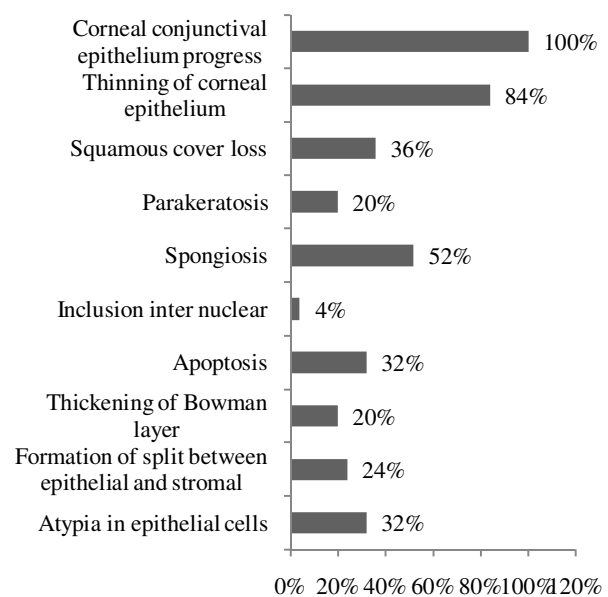


Diagram 1- Pathological changes of corneal epithelium (optical microscopic)

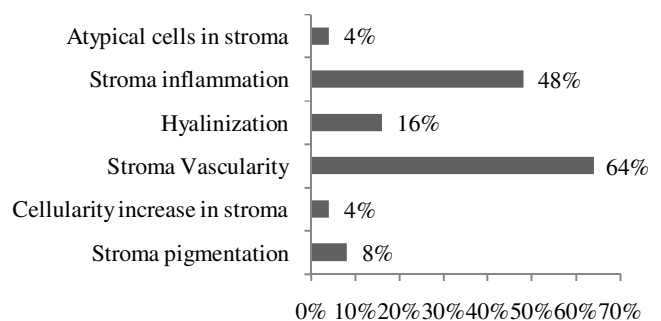


Diagram 2- Pathological changes of corneal stroma (optical microscope)

Results

Twenty-one of the injuries were men and one of them was woman. The youngest was 16 years old and the

oldest one was 48 years old, while the average age was thirty-five years old. The involvement time since facing mustard gas was between 14 to 16 years and the average length of their conflicts was 14.7 years old. The patients were treated with topical treatment such as artificial tears and betamethasone ointment.

In order to study by optical microscopic, four samples of paraffin blocks were crossed out due to insufficiency or being poor or aberrant. Some of these samples contained tenon and therefore, were not valid for this study. Eight sample resin blocks were crossed out due to being insufficient for the study.

A total number of 16 samples from the right eyes and 9 samples from the left eyes were studied with optical microscope. Among these 25 samples, 19 cases contained conjunctiva.

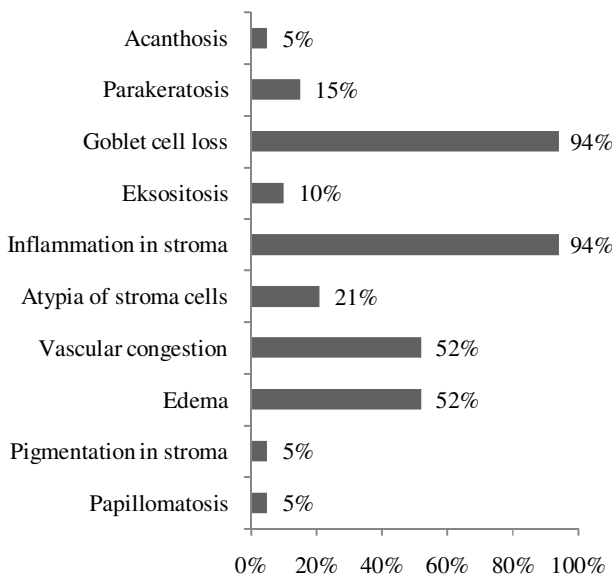


Diagram 3- Changes in conjunctival pathology

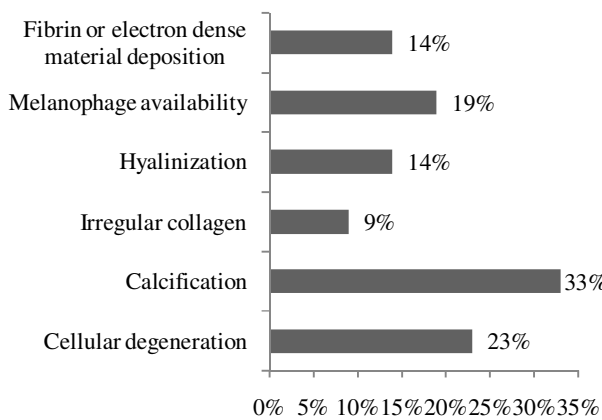


Diagram 4- Pathological changes in corneal stroma (electron microscope)

The patients had similar complaints and symptoms. The major complaints included photophobia, foreign body sensation, visual loss, and the symptoms of these patients included blepharitis, cornea epithelium deficiency, cornea opacity, and cornea scholarization, conjunctiva iskemia, thin conjunctiva, and reduced Schirmer test. The results from optical microscopic have been shown in diagrams 1, 2, and 3. Analyzing immune fluoescence was directly either negative or nonspecific in all samples. Moreover, no considerable antibody deposition was observed among epithelial cells on base membrane, around vessels, or other areas. The microscopic results are shown in diagrams 4 and 5.




Diagram 5- Pathological changes in corneal epithelium (electron microscope)

Discussion

Delayed Mustard Gas Keratopathy is the worst situation developed in eyes as a result of injuring with mustard gas and 250 cases of DMGK have been reported so far. In this disease, the relapse of the symptoms and corneal resistant ulcer are observed averagely between 10 -15 years after a long hidden phase. Considerable growth of corneal conjunctiva epithelium at the cornea surface is one of the

characteristics of this disease. This pathologic situation is approved by showing goblet conjunctiva in corneal [6, 7, 8, 9, 10]. Safai et al. reported changes such as squamous metaplasia, goblet cells metaplasia, and dysplasia in corneal cells [11]. The existence of stable conjunctivalization and the reconstruction of corneal epithelium and clinical improvements in patients suffering from this type of keratopathy, in case of replaced stem cells of Limbus area, is strong evidence on this claim that DMGK is created on the effect of acute performance or complete losing of Limbus area stem cells. In a study on one case of DMGK, Player et al. [4] reported the presence of basal cells and unnatural corneal epithelial and spindle shape keratinocytes in corneal anterior stroma in the vicinity of bowman layer, and they stated that they were connected to 3-D network of interwoven fibrils. At the end, they stated the immunity of the changed proteins and degenerative processes as probable reasons for delayed complications of mustard gas.

One of the stated questions in the present study was that whether or not these histopathologic and microscopic results of corneal tissue are limited to DMGK. In analyzing the samples with optical microscope, all the results were consistent with keratopathy caused by the defect of Limbus stem cells. Since the Limbus stem cells have been removed completely in this disease, the epithelium barrier facing with corneal is removed and the result is continuous and stable growth of conjunctiva epithelium on cornea. In the studied cases, in 100% of cornea of samples, the goblet cell was observed (conjunctivalization) in the present study, and the rest of the results were all consistent with the stable corneal ulcer. It is only possible to relate the clear atypia in the cores of some of the epithelium cells and isolated corneal stroma keratosis in samples without acute inflammation to the specific effects of mustard gas on corneal epithelium. These changes were completely similar to the changes observed after radiotherapy and chemotherapy of epithelial and non-epithelial cells in different tissues. It should be mentioned here that in none of the cases, the classic dysplasia or malignant changes was observed and the atypia reported in epithelium and stroma has been observed as isolated and sporadic.

Another question in this study was that whether or not one can find out the mechanism of this disease through microscopic study of samples suffering from DMGK at different levels. One of the hypotheses of creating DMGK was the defect of stem cells with mechanism of immune cells. During the study by optical microscope in corneal samples, the

inflammatory cells were seen in only 48% of the cases in corneal stroma, and the inflammatory infiltration in all the cases was a mixture of inflammatory chronic and acute cells. However, we know that in lesions created by the mechanism of cellular immune, lenfosits T are activated and stroke out against pure antigen in accompany with macrophages and do the cellular destructive process. Therefore, based on the results of this study, cellular immune mechanism is not stated for the destruction of stem cells in DMGK.

The next question in the present study was the possibility of humoral immune interference in destructing the stem cells in DMGK. Regarding the fact that all the samples stained with different antibodies by studying the florscence microscope were negative, the specific antibody was not seen against any of the corneal tissue and conjunctiva components. Therefore, humoral mechanism cannot be responsible for destruction of stem cells.

In analyzing by electron microscope, may be the hardest part of this study, the most frequent results were witness of cell lesions including cellular reversible and irreversible injuries. Cellular edema, relative losing, or shortened and overspreaded cellular superficial microplicae, cytoplasm vacuolization, decrease of intercellular connection, and rise of materials like myelin in the cytoplasm of epithelial cells, are all signs of irreversible injuries of the cells. However, increasing number of dark cells and their presence in all layers of corneal epithelium indicated the aging of cells and inability of corneal tissue for suitable reconstruction of epithelium cover. Unnatural aggregation of interstitial filament in the cytoplasm of epithelial cells in areas free from goblet cell can be regarded as a sign of conjunctivalization. Therefore, the analyzed results by electron microscope prove that DMGK is caused by complete defect of transitive cells proliferation and Limbus stem cells.

Due to being nucleophilic and delayed effect of alkylation, mustard gas causes a serious harm to the stem cells with a direct effect on DNA and kernel proteins of Limbus stem cells and transitive proliferation cells in corneal puzzle layer. It also causes the reduction of age and destruction of these cells through the effect on the building and finally, it reduces the number of the cells. In the present study, it was observed that the effect of mustard gas in tomoral tissues is higher than other tissues. It was already mentioned that the combinations of mustard gas are radiomimetics. Therefore, the effects of mustard gas are expected to be higher on cells that have more ability to divide and distinguish. It also seems logical that the destructive effects of mustard gas are higher

and more acute in transitive proliferation cells in corneal basal layers and Limbus stem cells that have more half-life, longer cellular circulation, shorter S-phase period, and the highest ability of dividing and distinguishing in cornea, than other cover cells of cornea and conjunctive. Since the possibility of interference of the cellular immune mechanisms and humoral in DMGK have been removed in this study, it seems that the mustard gas causes gradual destruction and dysfunction of transitive proliferation cells defect in puzzle layer of cornea. Moreover, it causes a gradual destruction of Limbus stem cells and results in DMGK.

Conclusion

There is no specific and diagnostic result in the histopathologic or microscopic analysis for the delayed destructive adverse effects of mustard gas in eyes. According to our observations, the cellular immune or humoral cannot justify all the destructive effects resulting from mustard gas. It seems that the primary mustard gas effect of alkylolation on cell is the basis of its delayed complications.

References

- 1- Khateri SH. Statistical views on late complications of chemical weapons on Iranian civil war victims. Tehran: Janbazan Publication. 2001;85:1-4. [Persian]
- 2- Slidell FR, Hurst CHG. Long-term health effects of never agent and mustard: Medical aspects of chemical and biological warfare. USA: Army Medical Research Institute of Chemical Defense Press; 1997.
- 3- Vinay K, Abbas AK, Fausto N. Pathologic basis of disease. 7th ed. USA: Elsevier Saunders; 2000.
- 4- Elyasi H. Body injuries by sulfur mustard war agent. Tehran: Jahad Publication; 1993. [Persian]
- 5- Rasuli S, Jadidi K. Clinical evaluation of patients with DMGK after limbal allograft transplantation. Tehran: Medical University Press; 2000. [Persian]
- 6- Jacques J. First victims of pyrite. *New J Chem.* 1991;15:3-4.
- 7- Pleyer U, Sherif Z, Baatz H, Hartmann CH. Delayed mustard gas chromatography: Clinical finding and confocal microscopy. *Entomol Sci.* 1999;128(4):506-7.
- 8- Gilbert S, Richard A. The cornea: Scientific foundations and clinical practice. 3rd ed. USA: Brown Company; 1994.
- 9- Puangsricharern V, Scheffer CG. Tseng cytologic evidence of corneal disease with limbal stem cell deficiency. *Ophthalmology.* 1995;102:1476-85.
- 10- Dua HS, Saini JS, Azuara-Blanco A. Limbal stem cell deficiency: Concept, aetiology, clinical presentation, diagnosis and management. *Indian J Ophthalmol.* 2000;48(2):83-92.
- 11- Safai A, Salati R, Kumar PV. Conjunctival dysplasia in soldiers exposed to mustard gas during the Iraq-Iran war. *Acta Cytologica.* 2001;45(6):909-13.